

Spondylosis

Siemens go.All

Application Examples: degenerative disease, evaluate facet joints	
Scan Protocol (See for Technical Factors)	L-Spine

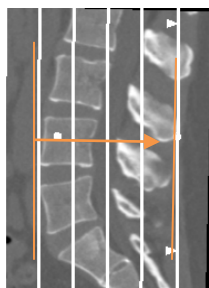
Spondylosis is a degenerative disease affecting the facet joints and the intervertebral discs. Spondylosis is not to be confused with spondylolysis, which is a type of fracture of a part of a vertebra that may or may not lead to spondylolisthesis (slippage of the cracked vertebra over the one below it).

Patient Position: Patient lying in supine position, arms positioned comfortably above the head, lower legs supported. Place a cushion under the patient's knees—this will reduce the curve in the spine and help make the patient more comfortable.

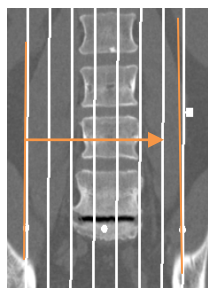
Scan Range: One vertebral level above and below area of interest or as specified by Radiologist or ordering provider.

2D Reformations: Coronal, sagittal, right and left oblique MPRs as depicted below.

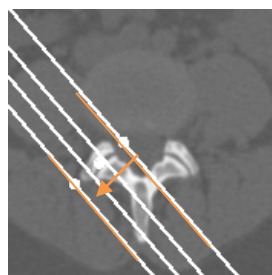
1. Coronal MPR
3x3mm



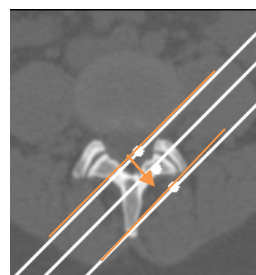
2. Sagittal MPR
3x3mm



3. Oblique RT MPR
2x2mm
(through right facet joints)



4. Oblique LT MPR
2x2mm
(through left facet joints)



Series Descriptions: **OBL RT**
OBL LT

3D: Upon request. See post processing protocol.